

EVALUATION OF ENDOPARASITISM IN FALLOW DEER (*DAMA DAMA L.*) FROM BIHOR COUNTY (ROMANIA) HUNTING GROUNDS

POPOVICI D.C.¹, MEDERLE N.², MARIN A.M.², MORARU M.M.F.², GHILEAN B.M.², IONESCU O.¹

¹Transilvania University Brasov, Forestry Faculty

²University of Life Sciences "King Mihai I" from Timisoara, Faculty of Veterinary Medicine

Abstract: 28 samples of fallow deer (*Dama dama L.*) from three different hunting grounds have been examined. The methods performed were the classical coprological methods, macroscopic and microscopic examination of the intestinal mass and organs. Following the examination, eggs and adults of **gastrointestinal nematodes** and *Dicrocoelium lanceolatum* have been identified. The results obtained draw attention to the epidemiological context.

Introduction

The fallow deer (*Dama dama L.*) is a notable representative of the *Cervidae* family in the Romanian fauna, particularly of the genus *Dama*, being an allogeneic species reintroduced into the country's fauna during antiquity by the Romans. The species do not live alone, at the habitat or ecosystem level they form a union, a conglomerate, together with other species between which various relationships or interactions are established. This interaction between two or more species takes various forms: competition, commensalism, mutualism, predation, or parasitism. From this point of view, the fallow deer (*Dama dama L.*) is no exception.

Material and method

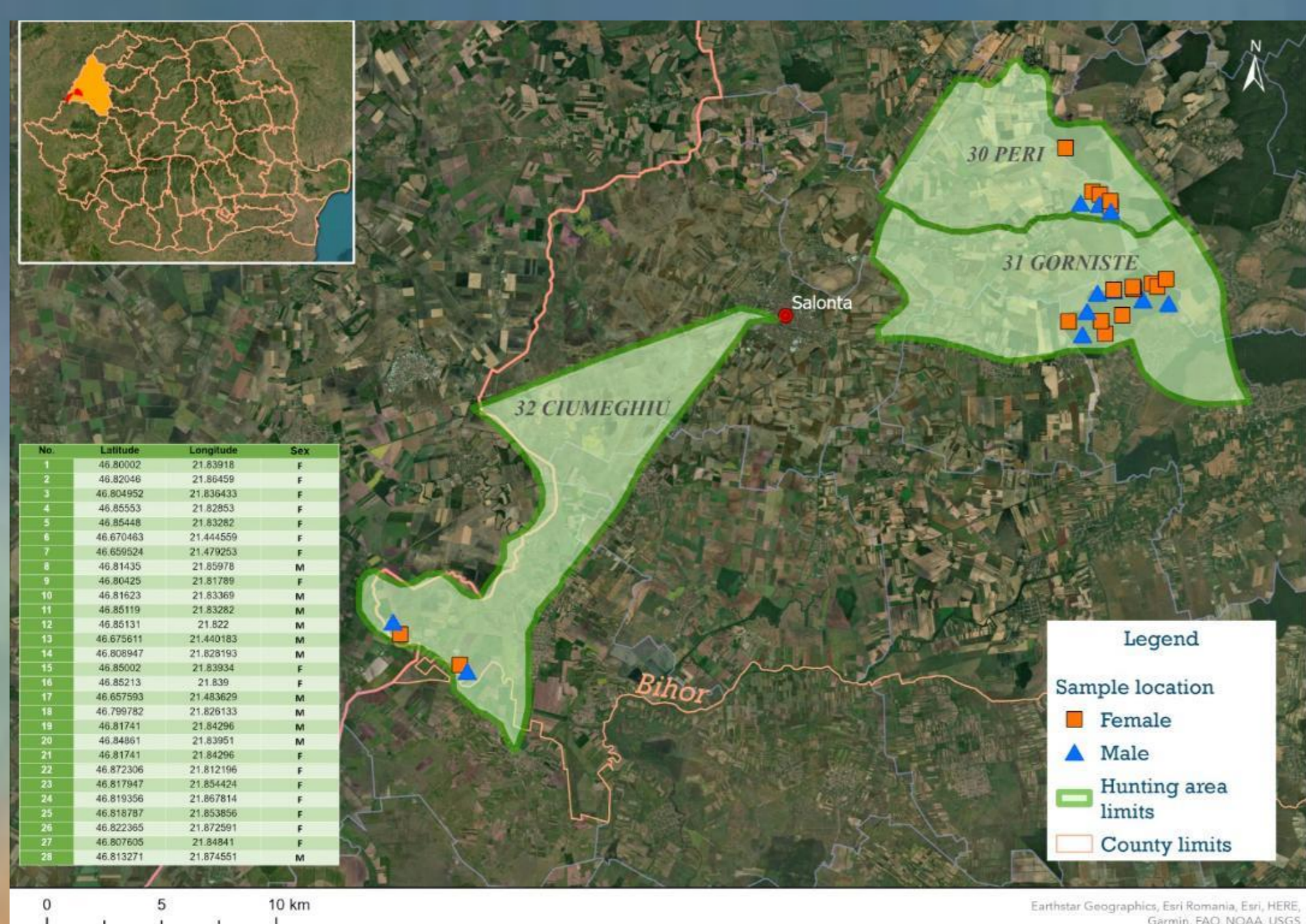
The purpose of the present study was to identify the presence of endoparasites in fallow deer from Bihor County and to evaluate the results obtained using classical coprological methods, macroscopic and microscopic examination of the intestinal mass and organs. 28 samples of fallow deer from three different hunting grounds were examined.

Results and discussions

The performance of the coprological examinations revealed the following results: the presence of **morulated eggs (gastrointestinal nematods) 64.29%**; the presence of *Dicrocoelium lanceolatum* eggs **10.7%**. By necropsy we identified **gastrointestinal nematodes in 18 (64.29%)** fallow deer, and the trematode *Dicrocoelium lanceolatum* **in 3 (10.7%)**.

Conclusions

The increased prevalence of endoparasitism in fallow deer with the risk of infestation of the domestic ruminants, indicates the existence of an epidemiological context favorable to the development of parasitic elements in Bihor County. This is a warning for domestic animal breeders, with possible repercussions on herds health and a decrease in production.



Acknowledgement:

This scientific paper was carried out in the Laboratory of Parasitology and Parasitic Disease at the Faculty of Veterinary Medicine Timisoara, Laboratory within the Animal Hygiene and Pathology Research Center/ ULS Timisoara.